

MANAGEMENT OF NEWBORNS ON THE POSTNATAL AND SPECIAL CARE NEONATAL WARD

Newborn Infant Physical Examination (NIPE)

- The UK National Screening Committee (UK NSC) policy for NIPE is that all eligible babies will be offered the NIPE screen. The screen should be offered within 72 hours of birth

Discharge from Labour Ward or the Neonatal Ward (RSCH and PRH)

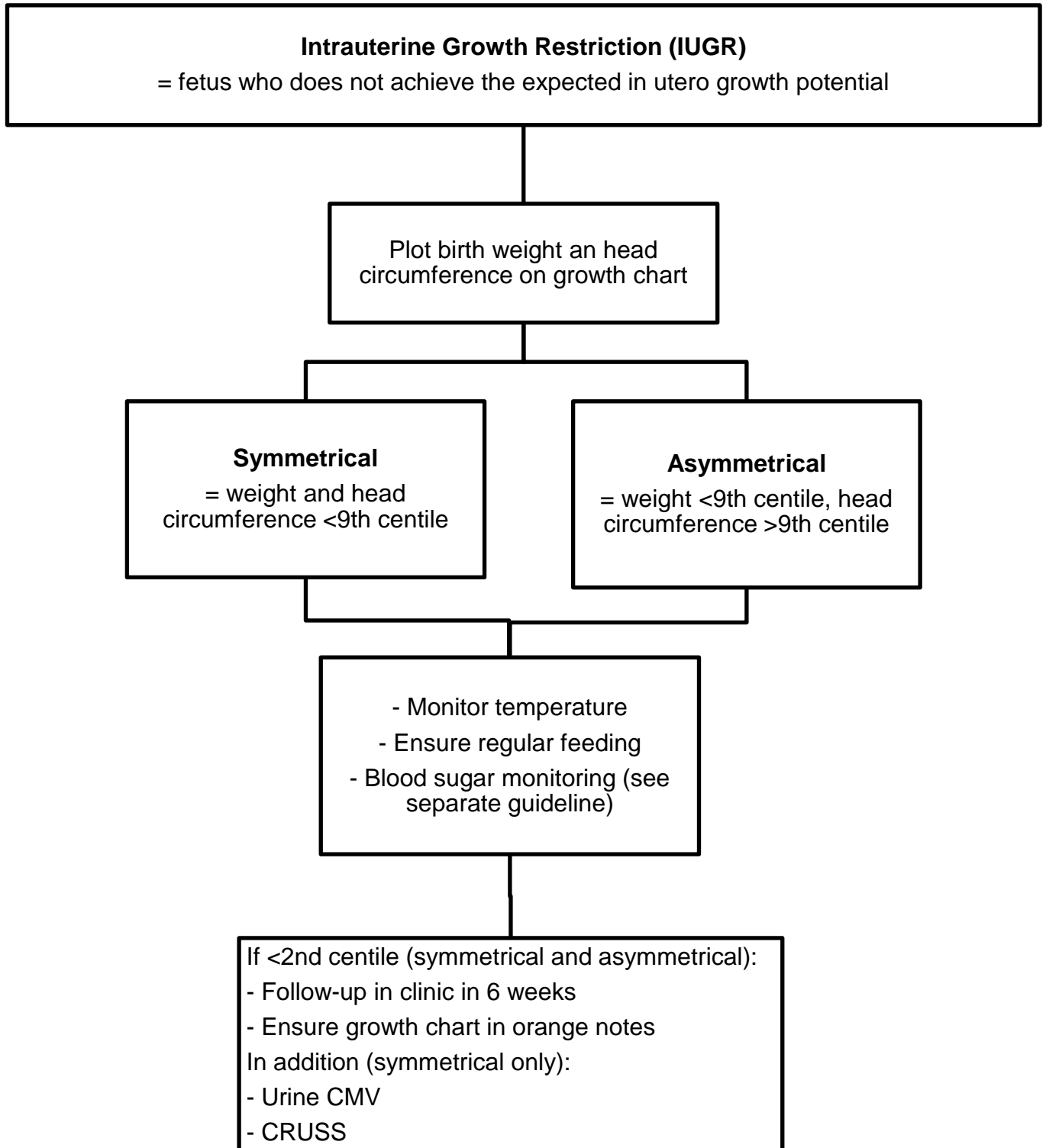
- All newborn infants should have a standardised physical examination by a qualified member of the neonatal or obstetric team prior to discharge home. Additional specific referral guidance for midwives trained in NIPE is given in a separate guideline. Please refer to: Examination of the Newborn: Referral Pathways for Midwives.
- The examination should preferably be performed when the infant is at least 35+0 weeks gestation to allow for sufficient physical maturity to be present that permits a safe and reliable examination without increasing the risk of causing harm from the examination or false negative/false positive results
- The examination should preferably be performed when the infant is at least 4 hours old to allow for cardiorespiratory stabilisation and the saturation screening. If a baby is discharged earlier, then a full examination and saturation screening should still be performed. If a problem is detected, the baby should be referred to a more senior member of the neonatal team for review prior to discharge. Arrangements must be in place for follow up of the problem.
- The member of the neonatal team should be notified as soon as possible if a mother wishes for a 4 hour discharge. Between 5.00 pm and 9.00 am weekdays, 3.00 pm - 9.00 am Saturdays and Sundays there is only one junior member of the neonatal team on duty and their primary responsibilities are to the patients on the Neonatal Unit and resuscitations in Labour Ward. When there is a more urgent duty, they may not be able to perform the neonatal discharge check when requested.
- When a Midwife requests the member of the Neonatal Team to perform a discharge check, if the member of the Neonatal Team is not immediately available they should request an estimate of how long it will be until the he/she is available and ask the parents to wait.

Referrals

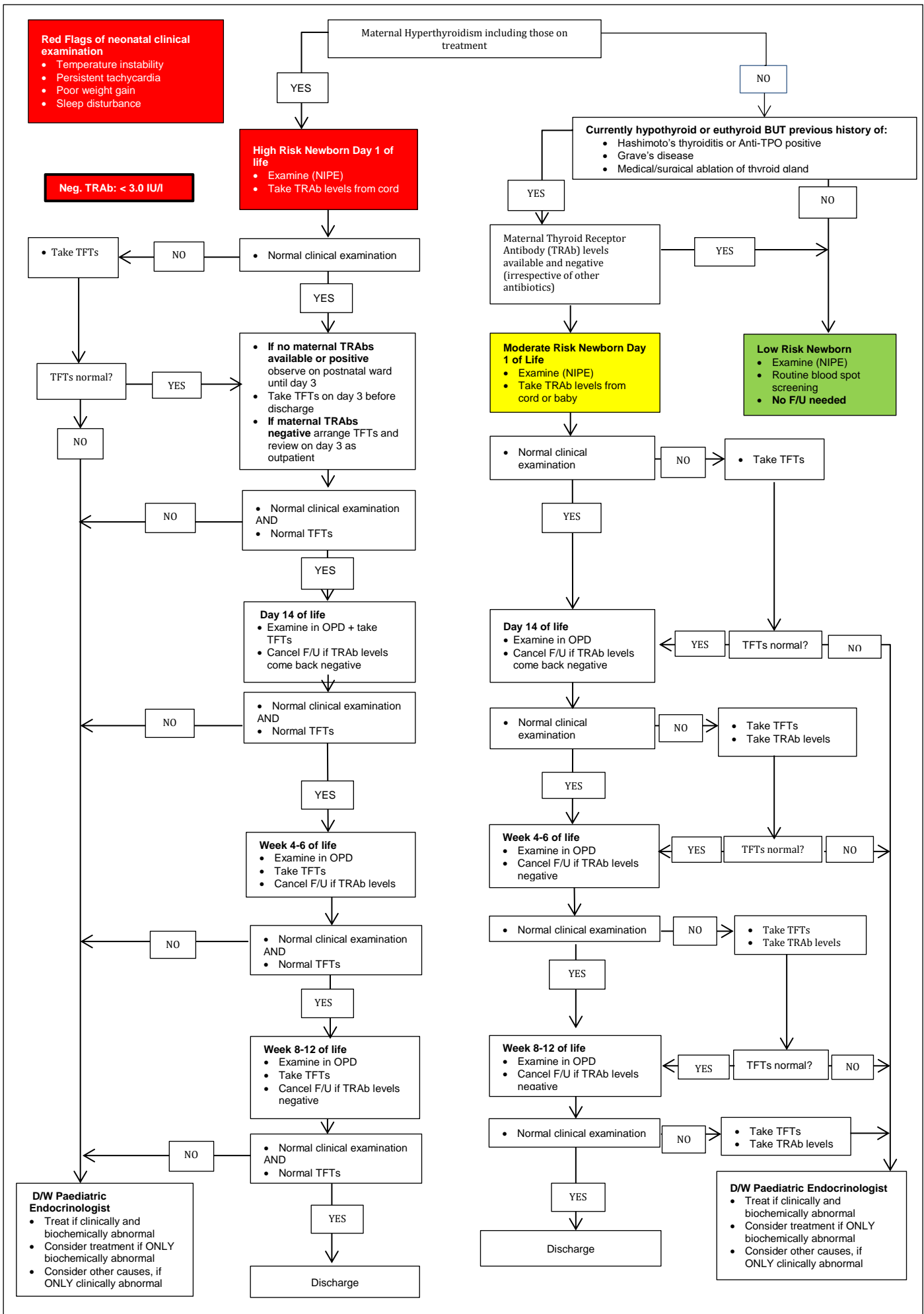
- All referrals to other services need a NIPE referral letter generated and a set of orange notes created. Save a copy of the referral letter to the NIPE folder on the shared drive.
- Blood results requested on the postnatal ward should be logged on the Postnatal Ward Results Folder on the TMBU SHO Drive (and checked regularly/actioned by the postnatal neonatal team)

Repatriation to Referring Unit

- Newborns below 35 weeks who are repatriated to their referring unit should have information in the BADGER letter summary outlining whether NIPE is pending or complete.
- Newborns below 35 weeks who are repatriated to their referring unit should be transferred out to the referring unit on the NIPE system. This will enable the colleagues in the referring unit the completion of NIPE before discharge home.
- Newborns who are at least 35+0 weeks gestation should have their NIPE completed as soon as possible and printed out before transfer and handed to the Transport Team with the BADGER letter.

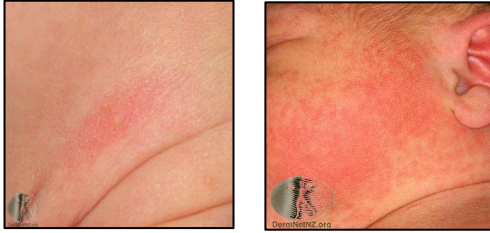


Maternal Thyroid Disease



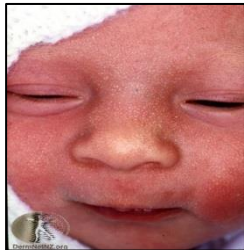Skin

Erythema Toxicum Neonatorum



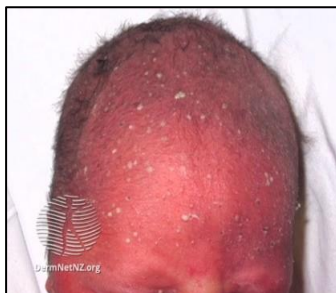- Aetiology is unknown, approx 50% of term infants affected
- Multiple erythematous macules and papules that rapidly progress to pustules on an erythematous base, spares palms and soles
- Appear yellow at blanching
- Resolves spontaneously

Milia



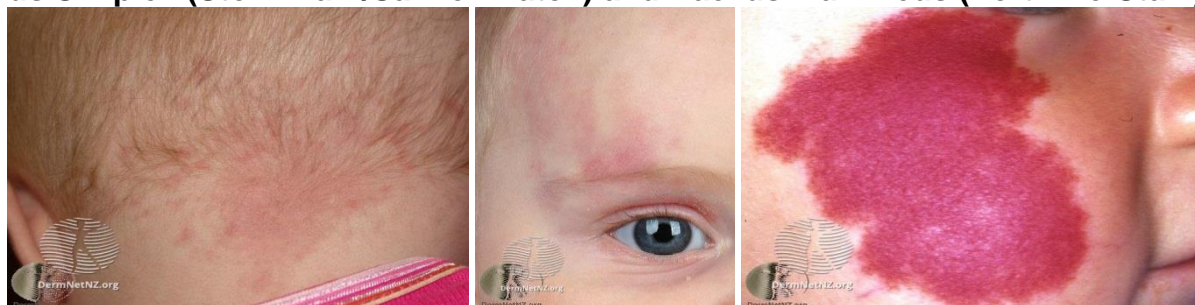- Tiny white spots, blocked pores, appear in 50% of term infants
- May also occur on the hard palate (Bohn's nodules) or on the gum margins (Epstein's pearls)
- Resolve spontaneously

Transient Neonatal Pustular Melanosis



- Uncommon benign pustular condition
- Pustules are present at birth, they can evolve but new lesions do not appear after birth
- Appear in 3 stages:
 - Small pustules on a non-erythematous base; these usually are present at birth
 - Erythematous macules with a surrounding collarette of scale develop as the pustules rupture and may persist for weeks to months
 - Hyperpigmented macules that gradually fade over several weeks to months
- No treatment is required, self-resolving

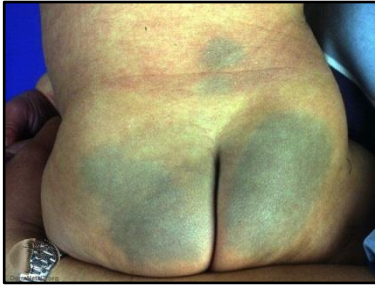Naevus Simplex (Stork Mark/Salmon Patch) and Naevus Flammeus (Portwine-Stain)



- Naevus simplex is very common (40%), usually small flat patches of pink or red skin with poorly defined borders, typically on nape of the neck, forehead between the eyebrows, eyelids

- Naevus simplex is more intense in colour and noticeable when the child is crying; most resolve within 1st year of life
- Naevus flammeus is much less common (about 0.3%), usually a large flat patch of purple or dark red skin with well-defined borders.
- At birth the surface of the port-wine stain is flat, but in time it becomes bumpy and often more unsightly. The face is most commonly affected although they can occur anywhere on the body. Where present, they generally appear on one side of the body with a sharp mid-line cut-off.
- May be associated with extra-cutaneous syndromes. Please refer naevus flammeus to local Dermatology Clinic or the Birthmark Clinic at GOSH if the face is affected

Blue Spots (Congenital Dermal Melanocytosis)



- Blue-black pigmented lesion, typically over sacrum/buttocks
- Usually the discolouration spontaneously resolves by 4years of age
- Important to document clearly in NIPE as can be mistaken for bruises

Congenital Melanocytic Naevus

- Congenital melanocytic naevi (CMN) occur in 1 to 3 percent of newborn infants; large or giant CMN occur in approximately 1 of 20,000 births
- Small- and medium-sized CMN are managed on an individual basis depending upon ease of monitoring (eg, color and location), clinical history, parents' anxiety, and cosmetic concerns.
- Large CMN are >9 cm on the head or >6 cm on the body and associated with the risks of cosmetic and psychosocial sequelae as well as the potential for malignant transformation. Please refer them to local Dermatology Clinic or Birthmark Clinic at GOSH

Sucking Blisters

- Caused by vigorous sucking by the infant whilst still in the womb.
- Intact blisters or erosions may be on the forearm, wrist, hands or fingers.
- Resolve within a few days

For images/further information:

- <https://www.dermnetnz.org/topics/skin-conditions-in-newborn-babies>
- <https://www.dermnetnz.org/topics/lumbosacral-dermal-melanocytosis>
- <https://www.dermnetnz.org/topics/transient-neonatal-pustular-melanosis/>
- <https://www.dermnetnz.org/topics/capillary-vascular-malformation>

Skin Tags

- Refer to Paediatric Surgeons at RAH

Head

Caput Succedaneum

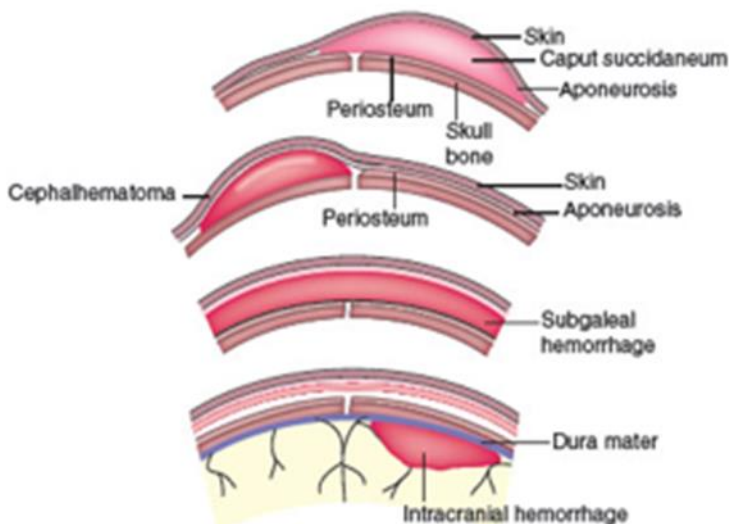
- Oedematous swelling of the scalp due to pressure of the presenting part against the cervix
- Crosses suture lines, may have skin discolouration (ecchymosis)
- Should resolve within 24-48 hours

Cephalohaematoma

- Subperiosteal collection of blood caused by rupture of blood vessels beneath the periosteum (usually over parietal or occipital bone)
- Often associated with assisted delivery (forceps/or ventouse)
- Does NOT cross suture lines
- Does not cause significant blood loss
- Will resolve spontaneously over a few weeks
- These infants may develop jaundice as the cephalohaematoma resolves

Subgaleal Haemorrhage

- Results following **traction injury** causing shearing/severing the emissary veins between the scalp and dural sinuses. Blood accumulates between the periosteum of the skull and the aponeurosis
- Diffuse fluctuant boggy scalp swelling developing over 12-72 hours
- Crosses the suture lines
- Can extend from orbital ridges to the nape of neck & to the level of ears
- Swelling may obscure the fontanelle
- Risk of haemorrhagic shock as the volume of blood can accumulate in the potential space. A loss of 20–40% of blood volume results in acute shock. In a 3 kg infant, 20–40% is equal to 50-100 ml. The subgaleal space can hold up to 260 ml.
- If you think the infant has a subgaleal haemorrhage:
 - Senior review
 - Infant may need TMBU admission
 - Consideration for baseline FBC, haematocrit, clotting, and head circumference
 - Serial monitoring of FBC, and head circumference. It has been estimated that for every 1cm of head circumference growth, 40 ml of blood can be lost to the subgaleal space.



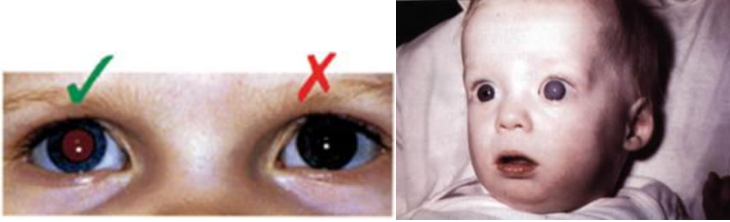
Craniosynostosis

- Premature fusion of cranial sutures affects 1:2000-2500 births
- Diagnosis mainly on physical examination
- Most common affected is sagittal suture (long thin head, ridge along length of the skull)
- Senior review if you suspect suture ridging and abnormal skull shape is not due to overlapping sutures
- Consider skull x-ray in three planes (including Towne) after senior review

Eyes

Absent Red Reflex or White Reflex (Leucocoria)

- Suggests the presence of a congenital cataract or retinoblastoma
- Senior review and contact Ophthalmology on EXT 64872 (Ms Barrett or Mr Heath)



Ears

National Hearing Screening (NHSP)

- The incidence of congenital hearing impairment is 1-2/1000
- All newborn babies will be screened with Oto-Acoustic Emission (OAE) and Automated Auditory Brain Stem Response (AABR) by the audiology team prior to discharge.
 - Risk factors: Family history of sensorineural hearing loss, BW<1000g, BW 1001-1500g and significant hypoxia, severe perinatal hypoxia, dysmorphic syndrome associated with hearing loss, abnormality of the ears, serious visual abnormalities, hyperbilirubinaemia requiring exchange transfusion, ventilation for more than a few days, congenital viral infection, neonatal septicaemia or meningitis, prolonged aminoglycoside therapy
 - Investigation of neonates diagnosed with severe/profound sensory neural hearing loss are urinary CMV PCR (first 21 days of life), plasma HSV PCR, plasma Rubella and Toxoplasma serology, Treponema Pallidum screening test (check with laboratory)
 - The maternal antenatal serological specimen if possible should be retrieved to allow comparative pre- and post-natal serology.
 - Please refer to Janine Blundell, Seaside View CDC for further investigations into aetiology and genetic counselling as well as ongoing management

Pre-Auricular Pits

- Small indentations located anterior to the helix and superior to the tragus of the ear
- Can be associated with unilateral hearing loss. Ensure routine audiology screening is done.

Accessory Auricular Appendage/Preauricular Tag

- Accessory appendages composed of skin, subcutaneous fat, and/or cartilage. When they occur in the preauricular area, they are called preauricular tags.
- Can be associated with unilateral hearing loss. Ensure routine audiology screening is done.
- Preauricular tags may be seen as part of several genetic conditions.

Mouth

Cleft Lip/Palate

- See information in blue CLAPA file. This file contains up-to-date parent information, guidance for feeding and notification/referral forms
- Referrals should be in the first instance to the Cleft Specialist Nursing Team on the telephone number **07548 152738**, alternatively e-mail Cleft.GSTT@nhs.net
- Following an initial visit from the nurse specialist team an appropriate appointment will be arranged with the CLAPA surgical team
- Genetic counselling will be offered to all parents who require it
- Arrange one neonatal appointment at 6 weeks

Teeth

- Refer to Orthodontist via switchboard if the teeth are not well secured and may be a potential aspiration risk, or if they pose problems with feeding as extraction may be considered

Heart

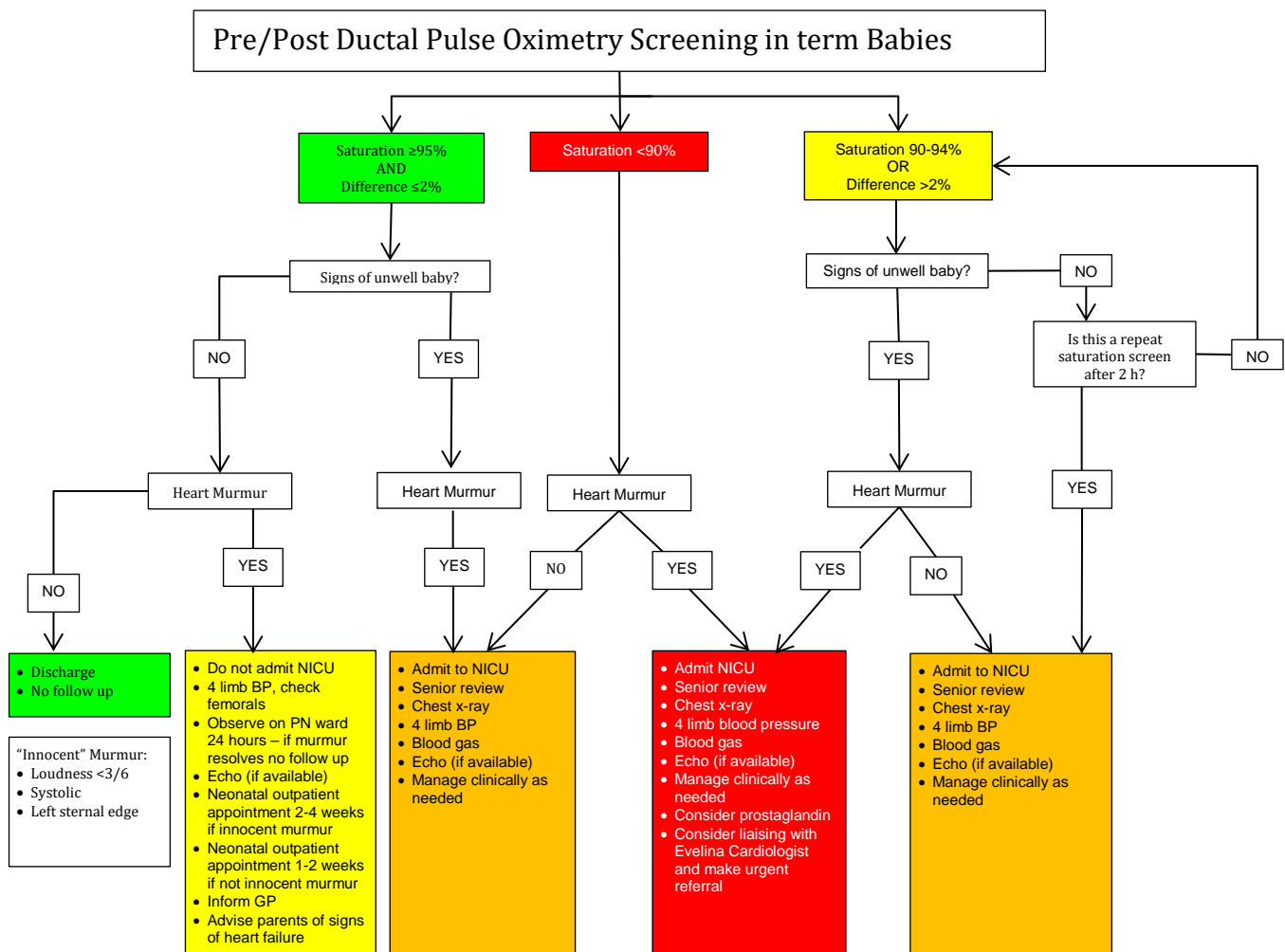
- The overall incidence of congenital heart defects (CHD) is 4-10/1000 live births
- The NHS NIPE Programme risk factors are:
 - family history of congenital heart disease (1st degree relative)
 - fetal trisomy 21 or other trisomy diagnosed (high risk of cardiac defects)
 - cardiac abnormality suspected from the antenatal scan

Family History of CHD/Antenatal History

- Obtain detailed family and antenatal history
- Check whether a postnatal plan has been made
- Perform careful clinical evaluation and follow flowchart as appropriate

Murmurs

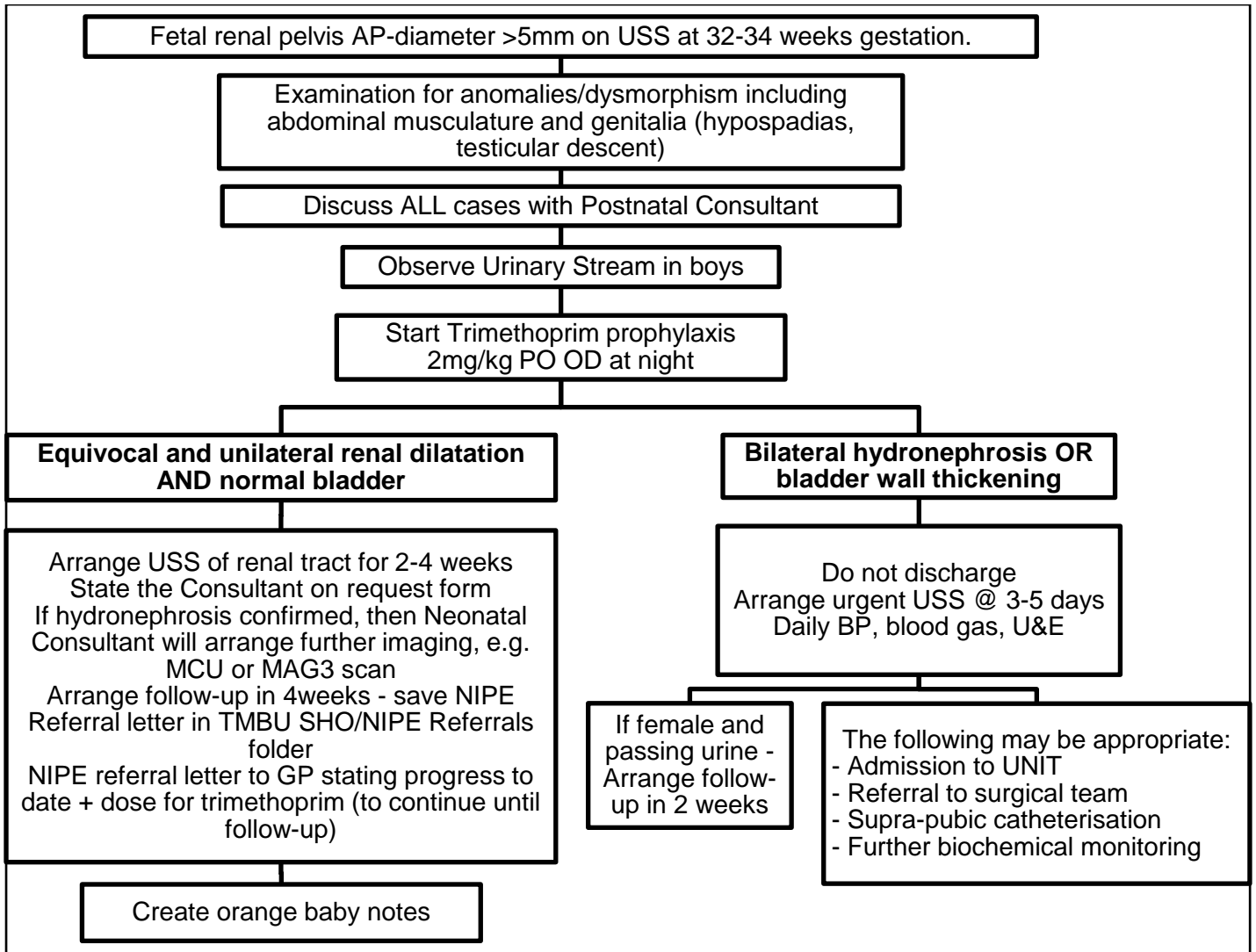
- Many babies will have cardiac murmurs in the first 24 hours of life in the absence of a cardiac defect (transitional physiology). There may be no murmur in babies with a cardiac defect.
- Follow flow chart and offer first F/U at approx. 2 weeks, then 6 weeks, then 12 weeks and every 8 weeks thereafter as long as baby is well. At 6 weeks refer for ECHO if murmur still present.



Renal

Hydronephrosis

- Fetal renal pelvis AP-diameter >5mm on USS at 32-34 weeks gestation
- Review antenatal letters, there will usually be a plan already made for difficult cases



- For those with equivocal scans if the postnatal US is abnormal further assessment should include measurement of BP and U+Es. May require urology referral to Mr Kalidisan or Mr Narayanaswamy

Genitalia

Undescended Testes

- Unilateral – request GP to review at 6-8 week examination
- Bilateral – requires review by senior member of the neonatal team and initiation of investigations prior to discharge, as may be associated with underlying endocrine problem; see Metabolic and Endocrine Guideline for further guidance

Hydroceles

- No surgical referral necessary, inform GP via NIPE referral letter

Hypospadias

- Refer to surgeons as outpatient via NIPE letter.
- Advise against circumcision
- Baby will usually be seen at one year of age

Ambiguous Genitalia

- Senior review and further investigation/admission
- See Metabolic and Endocrine Guideline for further guidance

Hernias

Umbilical Hernia

- Reassure: most resolve spontaneously by two years of age

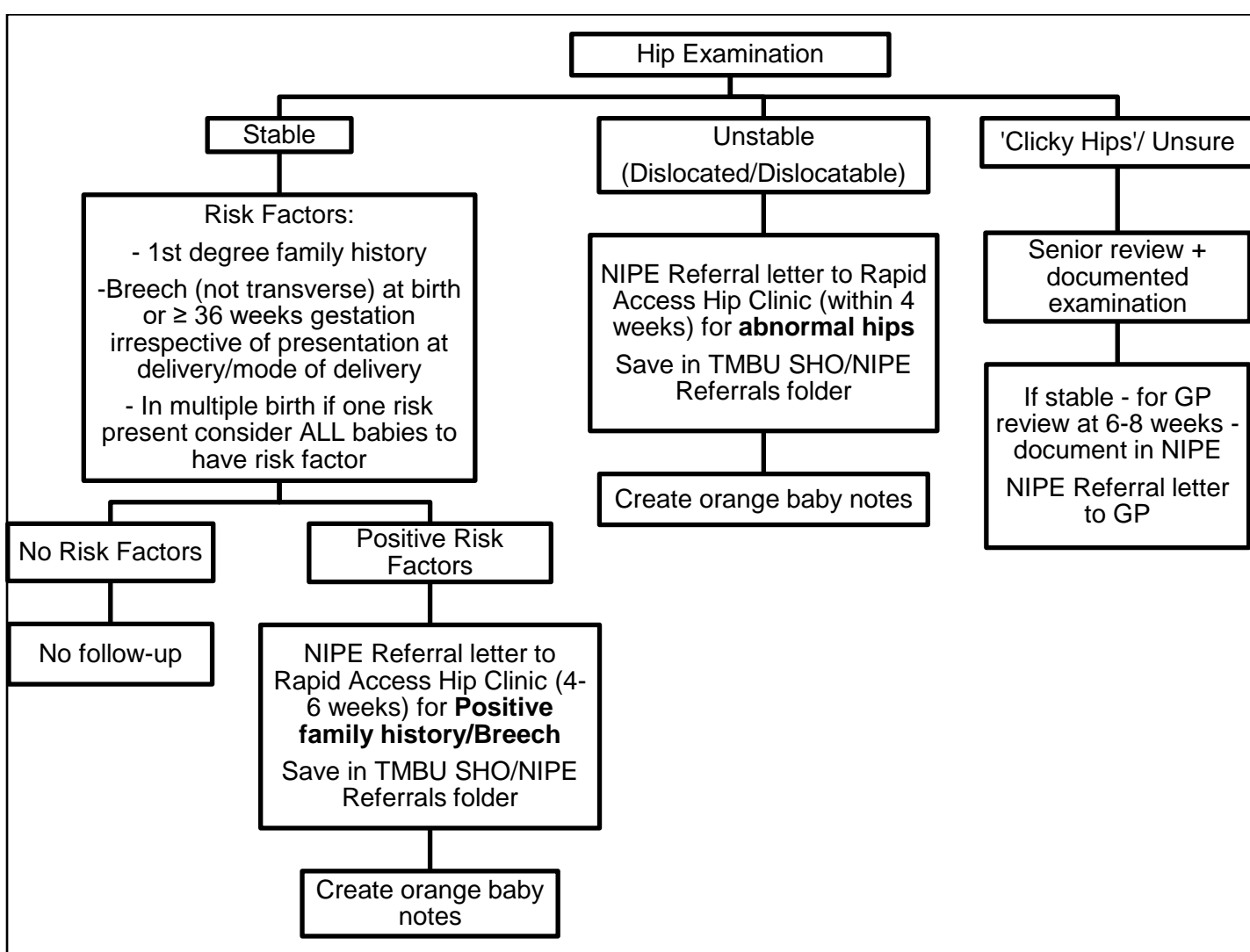
Para-Umbilical Hernia

- Refer to surgical OPC

Inguinal Hernia

- Refer to surgical OPC
- Incarcerated hernias should be seen by the Paediatric Surgical Registrar and not discharged
- Strangulated hernias are an emergency and require urgent attendance

Hips



- If the hips are still unstable following orthopaedic review, then they will be put in a Pavlik harness. 90% of babies with unstable hips at 2 weeks of age treated in this way have normal hips by 9 months of age.

Spine

Sacroccoigeal Pits/Sinuses

- Blind ending, sacroccoigeal pits/sinuses below S2 are normal and do not need referral
- If the sacral dimple is <2.5 cm from the anus and >5mm from the midline and <5mm deep, then no further action or investigations are required, even if the base of it cannot be seen
- Arrange spine ultrasound with Paediatric Radiology (as soon after birth as possible) if:
 - >2.5cm from anus or <5mm from the midline or >5mm deep
 - other signs of spinal dysraphism (e.g. anorectal malformation or cloacal anomaly)
 - the dimple is discharging
 - there are neurological signs
- Suspect occult spinal dysraphism with skin/subcutaneous tissue abnormalities over the spine
- If in doubt, ask for senior review in the following cases:
 - Cutaneous dimples or sinuses above the level S2
 - An abnormal collection of hair, a “tuft”
 - Haemangiomas, pigmented macules, sacral aplasia or tags
 - Subcutaneous masses including lipomas
- Check for neurological signs in the lower limbs, patulous anal canal etc and whether the baby has passed urine and opened bowels

Midline Defects

- Segmental haemangiomas over the midline/lumbosacral spine may be associated with spinal dysraphism and/or anal or genitourinary anomalies, including tethered spinal cord, lipomyelomeningocele, bony anomalies of the sacrum, abnormal genitalia, imperforate anus with fistula formation, or renal abnormalities
 - Thorough clinical examination
 - Midline spinal haemangiomas should have a spinal USS and be seen in follow-up clinic

Upper and Lower Limbs

Brachial Plexus Injury and Erb's Palsy

- To be seen by senior neonatal team member and discussed with Consultant prior to discharge
- X-ray clavicle and upper limb and refer to physiotherapist
- Review in Neonatal Follow-up Clinic at 2-4 weeks
- If the palsy hasn't resolved baby will need referral to Stanmore Orthopaedics

Syndactyly

- Webbing of skin this is usually familial, of no functional significance and requires no treatment
Refer to Plastic Surgeons at QVH (e-mail directly – tqv-tr.referrals@nhs.net FAO Mr Pickford)

Extra Digits

- Refer to Paediatric Surgeons or to Queen Victoria Hospital - do NOT tie off with silk

Talipes Equinovarus

- Fixed Deformity (the foot cannot be manipulated easily into the normal position):
 - All babies to be referred to Mr Maripuri/Mr Crompton's team and the physiotherapists asap
 - Aim for treatment to be started immediately – ideally within 48 to 72 hours of birth
 - If there is doubt, or the feet can only be returned to the normal anatomical position with difficulty, seek physiotherapy advice prior to discharge
 - Contact neonatal physiotherapist Emma Pavett by e-mail or neonatal orange physio folder at TMBU reception
- Positional talipes (when the foot can be returned to the normal position) - no treatment required

Calcaneovalgus Deformity

- Usually a positional deformity of the foot, rarely treatment needed, occasionally reverse strapping required
- Physiotherapist to see if you think this may be necessary

Overlapping Toes

- No treatment/strapping needed initially

- GP may refer at a later stage if felt to be a problem