

Ankle and lower leg injuries in children

Author: Darren Baldwin / Miki Lazner / Mr S N Maripuri / Mr T Crompton
Publication date: Sep 2020
Review date: Sep 2022

See also: knee injuries (microguide > paediatrics and neonatology > paediatrics > K)

Injuries covered in this guideline:

- **Ankle sprains**
- **Ankle fractures**
 - Lateral and medial malleolus fractures
 - Transitional fractures
 - Talar dome fractures
- **Proximal and distal tibial and or fibular fractures** (excluding injuries around the knee)
- **Toddler fractures**

Assessment

Any child with an ankle injury demonstrating neurovascular compromise must be referred immediately to the CED Consultant +/- Orthopaedic Registrar (Bleep 8629)

Ask about:

- Mechanism of injury, time of injury, site of pain
- After the injury: Immediate swelling? Able to weight bear? Treatments received
- Neurovascular symptoms: Paraesthesia or numbness? Pallor?

All children with ankle injuries **must be given adequate analgesia** before careful examination from knee to toe.

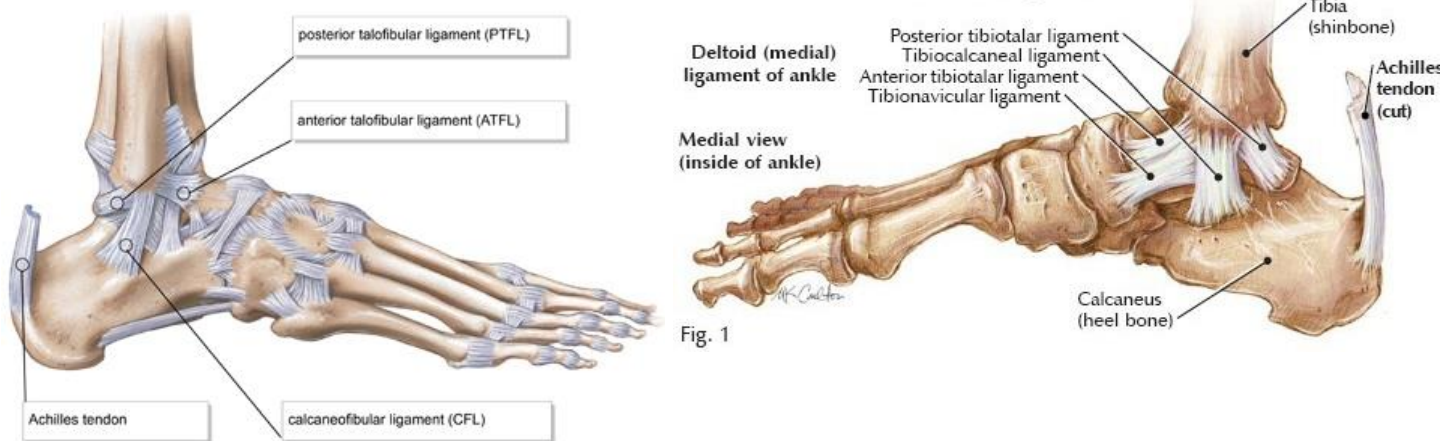
Use a **LOOK, FEEL, MOVE** approach.

Look - Observe the ankle for deformity, swelling, bruising and redness.

Feel – Ask which area is the most painful and examine that last.

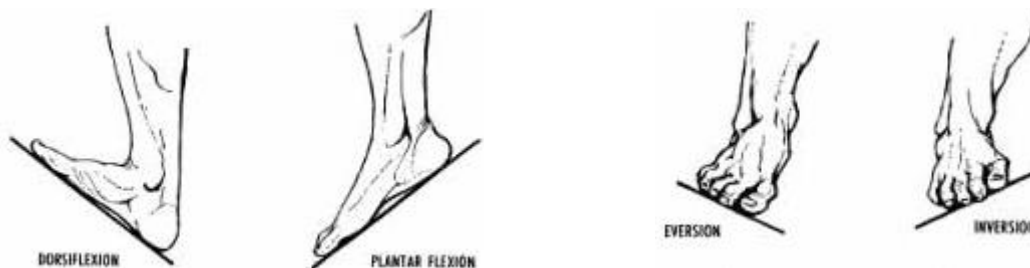- Ask the child to point with one finger where the pain is worst.
- Palpate all structures from the knee down trying to pinpoint bony tenderness;
- Key sites: head of the fibula (proximal), tibial shaft, fibula shaft, lateral and medial malleoli, anterior and posterior aspects of the ankle and the bones of the foot, especially base of 5th metatarsal and heel.
- If the history warrants it, check the calf muscle (gastrocnemius) and Achilles tendon.
- Check for tenderness over the medial and lateral ligaments

Caution: Tenderness both laterally and medially may indicate an unstable ankle.



Move – Test the range of movement (ROM) in the ankle joint.

- Is the child weight bearing?
- Can the child perform dorsiflexion and planter flexion, inversion and eversion movements of the ankle joint actively?
- Can you perform these movements passively and against resistance?



Imaging

Standard views are lateral and AP. Resist the temptation to do both foot and ankle x-rays at the same time. Decide where the injury is first.

- Ankle – for presumed injury to any of the bones in the ankle including talus, and calcaneal injuries.
- Foot – for presumed injury to base of 5th metatarsal and other bones in the foot
- Tibia and fibula – for presumed displaced / angulated tibia / fibula injuries and proximal injuries

Ankle injuries

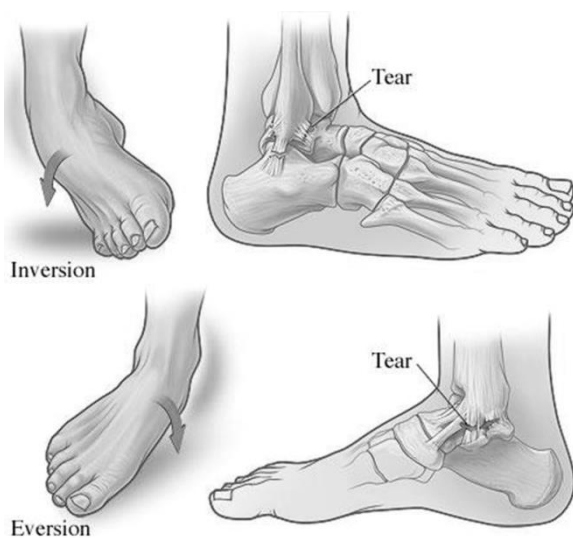
Background

- Soft tissue injuries of the ankle are common, but in small children, the ligaments of the ankle are stronger than the growth plates to which they are attached. Thus a **fracture is more likely than a ligament tear or sprain** – if in doubt, especially in younger children, x-ray.
- This is why in CED, the '**Ottawa ankle rules**' apply only to **children ≥ 12 years**.

- Teenagers can present with a special category of fracture called '**transitional fractures**' because they are in transition from adolescence to maturity.
 - Often involve the articular surface - **seek senior advice**.
- Most / all ankle injuries can be managed with a walking boot – but may be weight bearing or non-bearing (NWB).

Ankle Sprains

Majority result from inversion injuries of the ankle and are often sports injuries.



Sprains are divided into three grades:

- **Grade 1:** Mild injuries – result in tearing of some ligament fibres with minimal bleeding.
- **Grade 2:** Moderate injuries – result in incomplete rupture of the ligament and moderate bleeding.
- **Grade 3:** Severe injuries – characterised by complete disruption of the ligament.

Clinical Presentation

	Grade 1	Grade 2	Grade 3
Pain and activity	Can carry on with activity	Pain severe enough to stop activity	Pain severe enough to stop activity
Able to bear weight	Yes	Yes	No
Swelling	Mild	Moderate	Severe
Pain reproduced by stressing the ligament without laxity	No laxity	Some laxity	Gross laxity
Loss of functional and strength	No	Some	Possible

Management

1. **Analgesia is vital** if you want the child to weight bear in the department with a grade 1 or 2 sprain.
2. If child is NOT weight bearing – x-ray ankle to check for fractures
3. **If weight bearing in department:** discharge home with rest (minimal walking for the first 24 / 48 hours), ice, and elevation.
 - After 24-48 hours full weight bearing should be maintained with regular analgesia.
 - Give patient / parent the **CED ankle injuries leaflet** – provides post care information and exercises.
4. **If child is persistently unable or unwilling to weight bear in department (includes Grade 3 sprains), even after normal x-ray:** discharge home with walking boot that is kept on 24 hours, provide crutches and arrange virtual fracture clinic (may be Physio) follow up using the PANDA referral form.
5. **For all children:**
 - Encourage regular analgesia
 - Reinforce realistic expectations for recovery time
 - We do not expect simple ankle sprains to be pain free the day after or even the week after.
 - Sprains can take up to 6-8 weeks to heal properly and even then physiotherapy may be needed to maintain ankle strength.
 - Stress no participation in sports or high impact activities until the ankle is pain free and the patient is able to maintain normal balance on the affected ankle alone.

Ankle and lower leg fractures

If in doubt, have a low threshold for requesting x-rays. Young children in particular can have quite subtle signs for fractures.

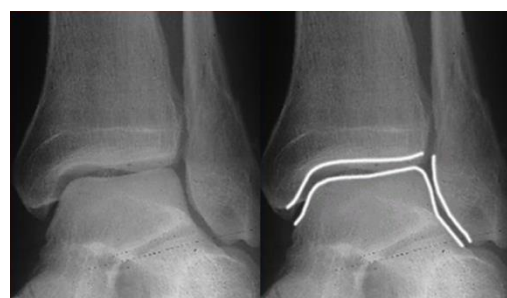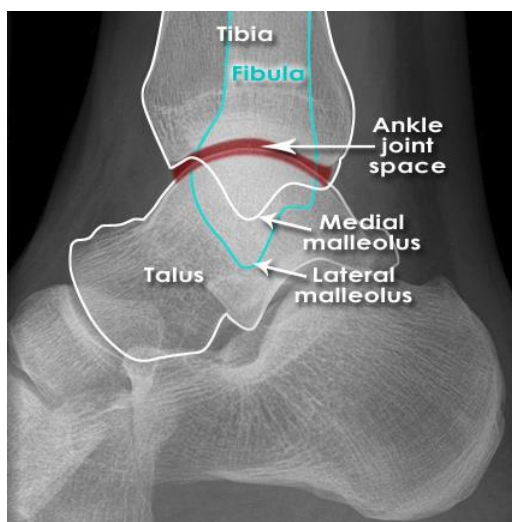
If unsure about x-ray findings, discuss with CED Consultant or ENP.

Ankle **fracture dislocation** is a neurovascular and limb threatening emergency: any child with an ankle injury demonstrating neurovascular compromise must be referred immediately to the CED Consultant +/- Orthopaedic Registrar on Bleep 8629.

Assessment

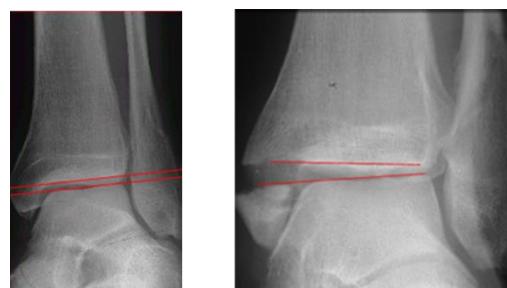NB Provide appropriate analgesia prior to assessment:

- Simple analgesia such as paracetamol and ibuprofen for minimal swelling / pain. Can add oral morphine if ongoing pain not relieved with simple analgesia.
 - Intranasal Fentanyl, intravenous morphine and Entonox for significant pain associated with deformity or significant swelling.
1. Observe the ankle for significant clinical deformity and angulation
 2. Check for presence of the posterior tibial and the dorsalis pedis pulses.
 3. Check sensation distal to injury
 4. X-ray ankle or tibia and fibula depending on area of concern. Consider a mortise view. Remember to check talar dome for osteochondral fractures.



AP mortise view

Clear space



Normal talar
tilt

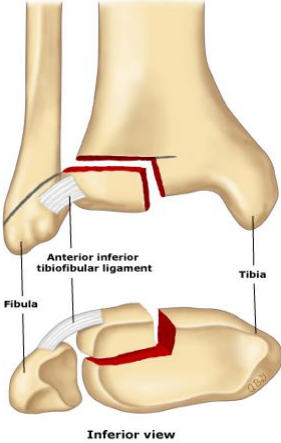
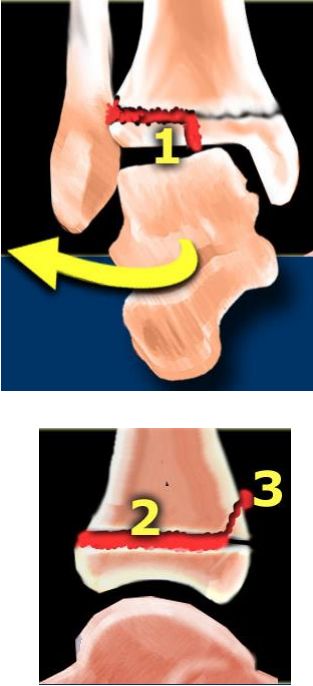
Abnormal talar
tilt


Management

Type of injury	Notes	Treatment
Fibular injuries		
Proximal fibular metaphyseal buckle fractures	<p>Usually in younger children. May be associated with proximal tibial buckle fracture (manage both bone fractures as detailed here)</p> <p>All tibial metaphyseal buckle fractures need virtual fracture clinic follow up due to risk of Cozen phenomenon - valgus angulation deformity of the tibia following a proximal tibial metaphyseal fracture. Late deformity.</p>	<ul style="list-style-type: none"> - Options: <ol style="list-style-type: none"> 1. No treatment 2. Bulky bandage (e.g. modified Robert Jones bandage with Softban and Easifix) 3. If severe pain – backslab - Can mobilise as pain allows - virtual fracture clinic follow up
Distal fibular metaphyseal buckle fractures	<p>Usually in younger children. May be associated with tibial buckle fracture (manage both bone fractures as detailed here)</p>	<ul style="list-style-type: none"> - walking boot and mobilise as pain allows - Backslab if not weight bearing or severe pain - virtual fracture clinic follow up
Distal fibular greenstick or complete fractures	<p>Look for tibial fracture</p> <p>Potentially unstable fractures</p>	<p><u>Minimally displaced or undisplaced fractures:</u></p> <ul style="list-style-type: none"> - below knee backslab and non-weight bearing (NWB) - virtual fracture clinic follow up <p><u>Displaced fractures:</u></p> <ul style="list-style-type: none"> - Backslab and NWB - refer Ortho Reg acutely
Lateral malleolus fractures	<p>Distal fibular avulsion fractures and undisplaced type I and II Salter Harris (SH) fractures are very low risk injuries for complications.</p>	<p><u>Distal fibular avulsion fractures or undisplaced Type 1 SH fractures:</u></p> <ul style="list-style-type: none"> - Treat as a sprain - If NWB – walking boot - virtual fracture clinic (may be Physio) follow up

Type of injury	Notes	Treatment
Lateral malleolus fractures cont.		<p><u>Minimally displaced or undisplaced Type II SH fractures:</u></p> <ul style="list-style-type: none"> - walking boot - virtual fracture clinic (may be Physio) follow up <p><u>Displaced Type I and II SH and all other fractures:</u></p> <ul style="list-style-type: none"> - walking boot and NWB - refer Ortho Reg acutely
Tibial injuries		
Proximal tibial metaphyseal buckle fractures	<p>Usually in younger children. May be associated with proximal fibular buckle fracture (manage both bone fractures as detailed here)</p> <p>All tibial metaphyseal buckle fractures need virtual fracture clinic follow up due to risk of Cozen phenomenon - valgus angulation deformity of the tibia following a proximal tibial metaphyseal fracture. Late deformity</p>	<p>Options:</p> <ol style="list-style-type: none"> 1. No treatment 2. Bulky bandage (e.g. modified Robert Jones bandage with Softban and Easifix) 3. If severe pain – backslab <ul style="list-style-type: none"> - Can mobilise as pain allows - virtual fracture clinic follow up
Proximal tibial greenstick or complete fractures	<p>Look for fibular fracture</p> <p>Potentially unstable fractures</p>	<p><u>Minimally displaced or undisplaced fractures:</u></p> <ul style="list-style-type: none"> - above knee backslab and non-weight bearing (NWB) - virtual fracture clinic follow up <p><u>Displaced fractures:</u></p> <ul style="list-style-type: none"> - Backslab and NWB - refer Ortho Reg acutely

Type of injury	Notes	Treatment
<p>Toddler fractures (see separate guideline on Microguide)</p>	<p>Undisplaced fracture of DISTAL tibial shaft with intact fibula in mobile young children, typically < 3 years.</p> <p>Ensure regular analgesia</p>	<p>Options:</p> <ol style="list-style-type: none"> Decision made to NOT immobilise: <ul style="list-style-type: none"> Allow child to mobilise when comfortable Follow up in ED review clinic 7–10 days Decision made to immobilise: <ul style="list-style-type: none"> toddler walking boot or long leg backslab if not available / correct size Follow up in virtual fracture clinic
<p>Distal tibia buckle fractures</p>	<p>Usually in younger children. May be associated with fibular buckle fracture (manage both bone fractures as detailed here)</p>	<ul style="list-style-type: none"> walking boot and mobilise as pain allows Backslab if NWB or severe pain virtual fracture clinic follow up
<p>Distal tibia greenstick or complete fractures</p>	<p>Look for fibular fracture</p> <p>Potentially unstable fractures</p>	<p><u>Minimally displaced or undisplaced fractures:</u></p> <ul style="list-style-type: none"> below knee backslab and non-weight bearing (NWB) virtual fracture clinic follow up <p><u>Displaced fractures:</u></p> <ul style="list-style-type: none"> Backslab and NWB refer Ortho Reg acutely
<p>Medial malleolus fractures</p>	<p>May be Type III SH fracture or occur after growth plate has fused.</p> <p>Typically accompanied by a distal fibular fracture.</p> <p>Look for talar shift on x-ray.</p>	<p><u>Undisplaced fractures:</u></p> <ul style="list-style-type: none"> Walking boot and NWB virtual fracture clinic follow up <p><u>Displaced fractures:</u></p> <ul style="list-style-type: none"> walking boot and NWB refer Ortho Reg acutely
<p>Type I and II SH fractures</p>	<p>Type I SH fractures of distal tibia are very rare; treat as per Type II fractures.</p>	<p><u>Undisplaced fractures:</u></p> <ul style="list-style-type: none"> walking boot and NWB virtual fracture clinic (may be Physio) follow up <p><u>Displaced fractures:</u></p> <ul style="list-style-type: none"> walking boot and NWB refer Ortho Reg acutely

<p>Type III SH fractures</p> 	<p>Juvenile Tillaux fracture – transitional fracture involving the antero-lateral aspect of distal tibia. Typically seen in 12-14 year olds when the distal tibial growth plate is partially fused.</p> <p>Growth plate fuses medially to laterally. Fracture line typically seen on AP view as vertical lucency through lateral epiphysis.</p> <p>Clinical clue is anterior joint line tenderness and swelling.</p>	<p><u>Undisplaced and displaced juvenile tillaux fractures:</u></p> <ul style="list-style-type: none"> - walking boot and NWB - refer to Ortho Reg acutely - Likely to require CT scanning
<p>Type IV and V SH fractures</p> 	<p>Involves the joint – requires Ortho input urgently.</p> <p>Triplane fracture – type of Transitional fracture. Type IV SH fracture involving the coronal, sagittal and transverse planes.</p> <p>Fracture line extends from above the growth plate, along the growth plate and out into the ankle joint.</p> <p>On lateral x-ray view, fracture line will be seen above the growth plate. On AP view, vertical lucency will be visible through the epiphysis.</p> <p>If undisplaced, may have minimal pain. Examine carefully for anterior joint line tenderness.</p>	<p><u>Undisplaced and displaced fractures:</u></p> <ul style="list-style-type: none"> - Walking boot and NWB - refer Ortho Reg acutely - Likely to require CT scanning

<p>Talar dome fractures</p> 	<p>Type of osteochondral fracture. Occur laterally or medially.</p> <p>Easily missed on x-ray.</p>	<p><u>Undisplaced or displaced fractures:</u></p> <ul style="list-style-type: none">- Walking boot and NWB- refer Ortho Reg acutely
--	--	--